

## Discharge/Operation Record

**Name :** Manish kumar Sharma M/29

**Indoor No :** I04316

**Date Of Admission :** 28-09-2022 **Date Of Op. :** 29-09-2022 **Date Of Discharge :** 30-09-2022

**Operated At :** Aash Arthroscopy Center

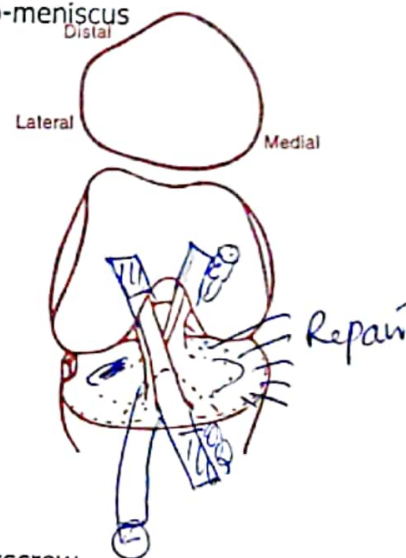
**Anesthetist :**

**Region :**

**Right Knee Operation :** ACL Recon-BPTB graft, PCL Recon-Hamstring, Meniscus repair & chondroplasty

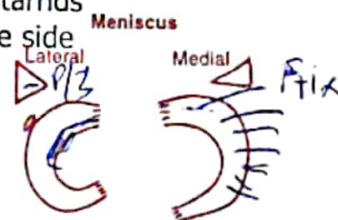
**Findings :**

- Completely absorbed ACL
- Stretched non functioning PCL
- Medial meniscus: Locked bucket handle tear- Capsulo-meniscus separation
- Lat. meniscus: Horizontal tear in P/3
- Articular cartilage affection:
  - \* MFC -Grade 3 in post. condylar area
  - \* LTC: Grade 3-4 in medial 1/2
- Synovitis & effusion



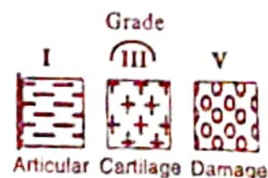
**Operation :**

- ACL reconstruction: Bone- Patella tendon- Bone graft ( 10 mm \* 80 mm, small incisions harvest, Femur: Biosscrew 8\*25; Tibia: 10\* 25 IF Tit.)
- PCL augmentation: Hamstring graft ( 8mm\* 90 mm-5 strands Femur: BioRCI: 8\*30 mm, Tibia: suture disk Adler, Same side grafts)
- Medial meniscus repair: 8 Insideout stiches & 2 fast fix
- Lat. meniscus debridement
- Chondroplasty
- PCL brace for 6 weeks



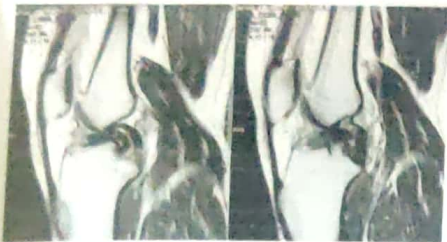**Instruction :**

- NWBWW- 15 days
- Regular exercises
- Weight reduction- 10 kgs in 6 months

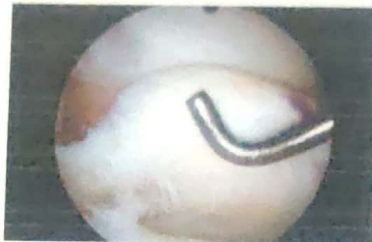

Patient ID: 2022090016  
Name: Mr. ManishKumar Sharma  
Surgeon: Dr. Nishith V Shah

Surgery ACL PCL reconstruction Meniscus Repair  
Date: 29-Sep-2022



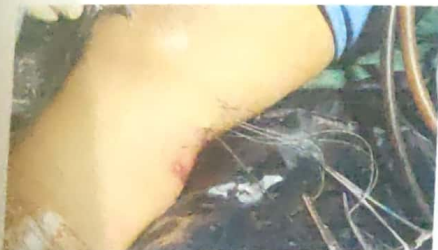MRI showing rupture of Ant. cruciate ligament (ACL) with a bucket handle tear of med. meni.



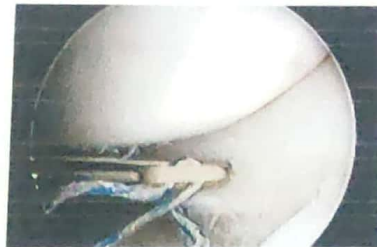Bucket handle tear of medial meniscus was seen that was producing locking



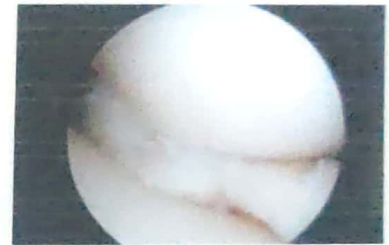Meniscus stabilization done by multiple inside out sutures. No more loose meniscus



Multiple stitches were placed in the meniscus to ascertain proper repair & meniscus preservation



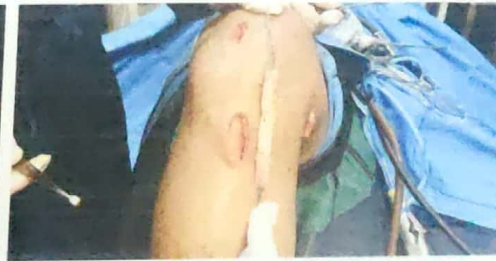Back part of the meniscus was repaired using all inside fastfix device to ensure better repair



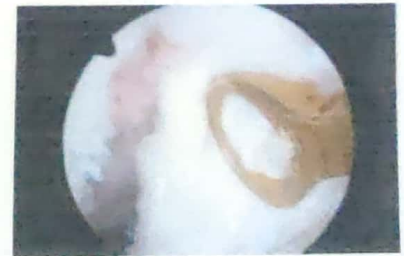Medial meniscus was relocated at its original position after the repair



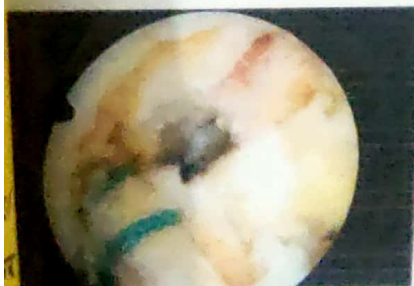Tear was also seen in outer cushion (lat. meniscus). This was trimmed.



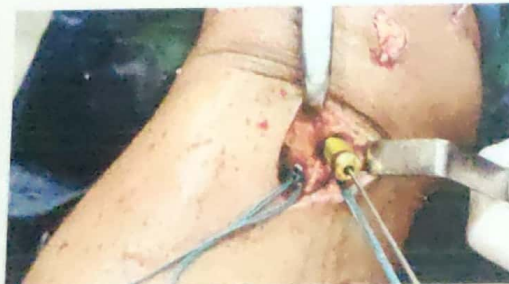Bone Patella Tendon bone graft was Harvested to reconstruct ACL. Hamstring grafts



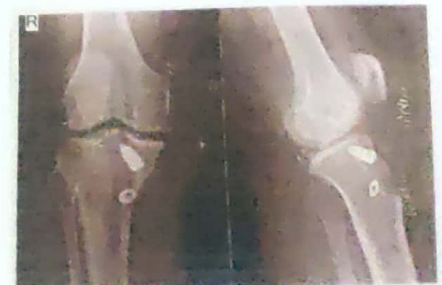Femoral jig in place with a drill pin. This ensured a perfect tunnel in the thigh bone



ACL & PCL were examined for its alignment as well as their tightness



Both ligaments were fixed on Tibia with titanium implants



Post operative X-ray showed perfect positioning of all tunnels with implants

Mobile: 9979844577